

Influence of free-water correction in DTI on the study of white matter changes in migraine

Irene Guadilla^{1,2}, Ana R Fouto², Álvaro Planchuelo-Gómez³, Antonio Tristán-Vega³, Amparo Ruiz-Tagle², Inês Esteves², Gina Caetano², Nuno A. Silva⁴, Pedro Vilela⁴, Raquel Gil-Gouveia⁴, Santiago Aja-Fernández³, Patrícia Figueiredo², Rita G Nunes²

1 Universidad Autónoma de Madrid, Spain;

2 Institute for Systems and Robotics – Lisboa and Department of Bioengineering, Instituto Superior Técnico, Universidade de Lisboa, Portugal;

3 Laboratorio de Procesado de Imagen (LPI), ETSI Telecomunicación, Universidad de Valladolid, Spain;

4 Hospital da Luz, Lisbon, Portugal.

Abstract

INTRODUCTION: Menstrual migraine affects 25% of female migraine patients [1]. These patients tend to experience regular attacks within 2 days before menstruation and the first 3 days of bleeding. Imaging techniques can be used to evaluate brain changes associated with migraine. Previous studies using diffusion tensor imaging (DTI) reported lower mean diffusivity (MD) values in migraine patients [2,3]. However, the diffusion signal may suffer from free-water (FW) contamination, which can hinder estimation of tissue properties. In this work, we considered a diffusion signal model with two compartments, hypothesizing a gain in sensitivity to detect white matter alterations of menstrual migraine patients from the DTI parameters estimated following FW elimination.

METHODS: Diffusion-weighted MRI (dMRI) datasets were acquired in a 3T Siemens Vida scanner. Female subjects, 15 healthy and 14 menstrual migraine patients without aura, were studied after ovulation and between migraine attacks, respectively. The dMRI sequence included 8 non-diffusion weighted volumes ($b=0\text{s/mm}^2$) and 2 shells ($b=400,1000\text{s/mm}^2$) along 64 gradient directions (32 for each b value). Data was pre-processed with the DESIGNER pipeline [4]. FW maps were calculated applying the spherical means method using dMRI-Lab toolbox [5]. Subsequently, the diffusion signal was corrected by subtracting the FW partial volume fraction, and DIPY's TensorModel tool [6] was used to calculate the DTI parameters from the corrected diffusion signal: MD and fractional anisotropy (FA). Parametric maps were skeletonized, and two-sample unpaired t-tests were carried out voxel-wise to compare tensor parameters (FA and MD) and FW between patients with controls, using FSL's TBSS [7].

RESULTS & DISCUSSION: The correction for FW fraction in the diffusion signal allows the detection of a higher number of voxels exhibiting significant differences in MD between patients and controls, over 12 regions. Comparison between the migraine patients and the healthy subjects identified significantly lower MD values in the white matter skeleton of patients in comparison with controls (Figure 1), although not changes in FA, suggesting abnormal white matter properties.

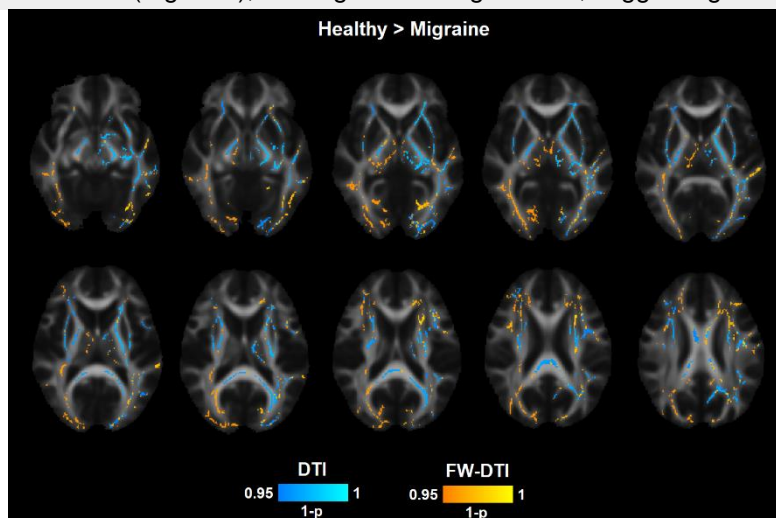


Figure 1. Statistically significant differences in Mean Diffusivity (MD) in white matter regions. MD values were higher for healthy subjects compared to patients from (light blue) original DTI and (yellow) FW-DTI. Grayscale: fractional anisotropy map; yellow: (1-p)-value, light blue: (1-p)-value.

References

- [1] Vetvik et al. The Lancet Neurology, 2021, 20(4):304-315.
- [2] Yu et al. Cephalalgia, 2013, 33:34-42.
- [3] Rocca et al. J.Neurol. Neurosurg. Psychiatry 2003, 74:501-503.
- [4] Ades-Aron et al. Neurolmage 2018; 183:532-543.
- [5] Tristán-Vega et al. Magn Reson Med. 2021; 87:1028–1035.
- [6] Chang et al. Magn Reson Med 2005; 53:1088-95.
- [7] Smith et al. Neurolmage 2006, 31:1487-1505.

Acknowledgements

This work was supported by Ministerio de Ciencia e Innovación PID2021-124407NB-I00 and TED2021-130758B-I00, funded by MCIN/AEI/10.13039/501100011033 and the European Union NextGenerationEU/PRTR, and Margarita Salas grants CA1/RSUE/2021-00801 from Universidad Autónoma de Madrid, Spain. We acknowledge the Portuguese Science Foundation through grants PTDC/EMD-EMD/29675/2017, LISBOA-01-0145-FEDER-029675 and UIDB/50009/2020.